



PATIENT PRESENTING CLINICAL SIGNS

PATIENT Nugget Flowers Presenting Complaint: Nugget presents for limping on the left hind limb and licking at the right hind paw

SPECIES

Canine

BREED

Terrier Mix

SEX

MN

AGE

6yr

INTERPRETED BY

Nele Eley (Ondreka),
DVM Dr. med. vet.,
DipECVDI

HOSPITAL NAME

Green Dog Dental &
Wellness

REFERRING VET

Dr Geist

INVOICE

24836

DATE

05/13/2026

Patient History: Left hind limb: favoring for approximately 3 months, would lift and hike it intermittently, now limping

Right hind paw: licking consecutively since Monday Recently groomed on Friday with no issues noted at that time

Abnormal PE/Chem/CBC/UA Results: Right hind paw P3 of 3rd digit pain/edema and luxated nail r/o pododermatitis/bacterial infection, nail bed infection, trauma, mass Left medial patellar luxation grade 2-3 - r/o congenital luxation, degenerative joint disease

RADIOGRAPHIC STUDY OF THE

Radiographic study of the stifles and hind paws, mediolateral and craniocaudal views of the stifles and hind paws available for review.

RADIOGRAPHIC FINDINGS

LEFT STIFLE

Medial patellar luxation is noted with the patellar position medial to the trochlear groove. Mild osteophytosis is present at the femoral trochlea, consistent with early degenerative change. No significant joint effusion is identified. No evidence of tibial or femoral angular deformity is seen. There is no evidence of tibiotarsal angular limb deformity.

Overall appearance is most consistent with congenital or developmental medial patellar luxation with mild secondary osteoarthritic change.

RIGHT STIFLE

Osseous alignment is normal. The patella is appropriately positioned in the trochlear groove. No evidence of osteophyte formation, joint effusion or tibial translation is seen.

RIGHT HIND PAW

Circumferential soft tissue swelling is centered on the distal phalanx of digit 3. No aggressive lytic or proliferative osseous changes of the third phalanx or of the distal phalanx are identified. The nail bed region may be mildly irregular. Findings are most compatible with inflammatory or traumatic soft tissue injury.

RADIOGRAPHIC DIAGNOSIS

- Medial patellar luxation with mild femoral trochlear osteoarthritic formation of the left stifle joint most consistent with congenital /developmental medial patellar luxation with early degenerative joint disease.
- Radiographically normal right stifle
- Soft tissue swelling surrounding P3 of digit 3 right hind without radiographic evidence of aggressive osseous disease.



PATIENT INTERPRETATION OF FINDINGS & FURTHER RECOMMENDATIONS

Nugget Flowers The findings of the left stifle joint are compatible with congenital /developmental medial patellar luxation with early degenerative joint disease. No significant effusion or secondary major joint pathologies identified at this point. Clinical correlation is recommended.

SPECIES

Canine The findings of the right hind paw are most consistent with pododermatitis, nail bed infection or soft tissue trauma of the third digit. No signs of aggressive bone disease are seen at present.

BREED

Terrier Mix

SEX

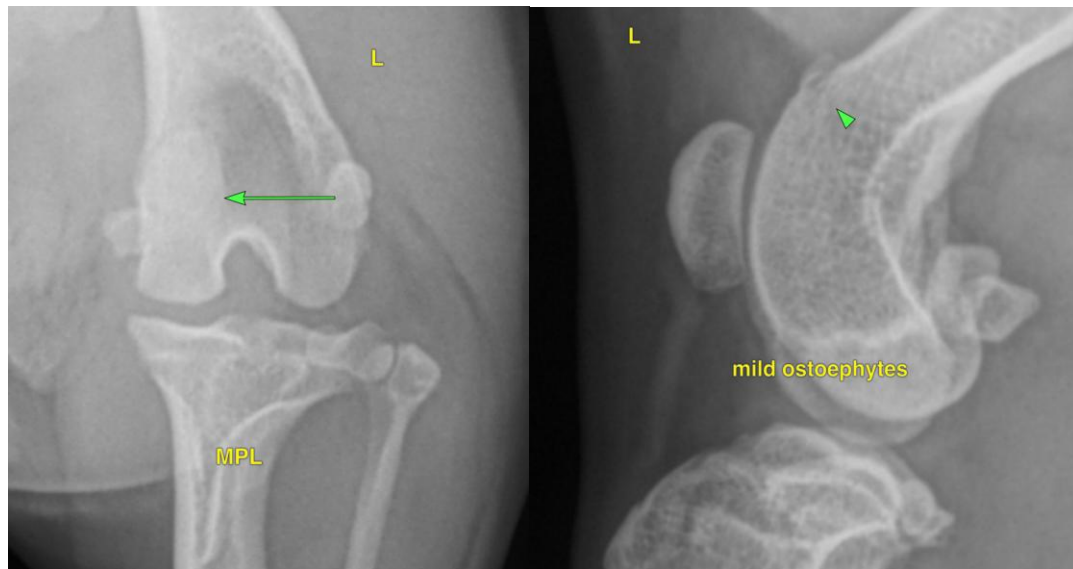
MN

AGE

6yr

INTERPRETED BY

**Nele Eley (Ondreka),
DVM Dr. med. vet.,
DipECVDI**



The information and recommendations provided are based on the images presented by the referring veterinarian. No evaluation can be communicated regarding pathology that was not visible in the image/video clips provided.

HOSPITAL NAME

**Green Dog Dental &
Wellness**

Thank you for this referral. If the clinical or image interpretation does not parallel your findings or if I can be of any further assistance please contact me.

REFERRING VET

Dr Geist

Nele Eley (Ondreka), DVM, Dr. med. vet., DipECVDI
European Specialist in Veterinary Diagnostic Imaging, Cert. Radiology,
Senior lecturer University of Giessen/Germany, Veterinary Faculty, Department of Radiology.
info@sonopath.com

INVOICE

24836

DATE

05/13/2026



PATIENT

Nugget Flowers

SPECIES

Canine

BREED

Terrier Mix

SEX

MN

AGE

6yr

INTERPRETED BY

Nele Eley (Ondreka),
DVM Dr. med. vet.,
DipECVDI

HOSPITAL NAME

Green Dog Dental &
Wellness

REFERRING VET

Dr Geist

INVOICE

24836

DATE

05/13/2026